

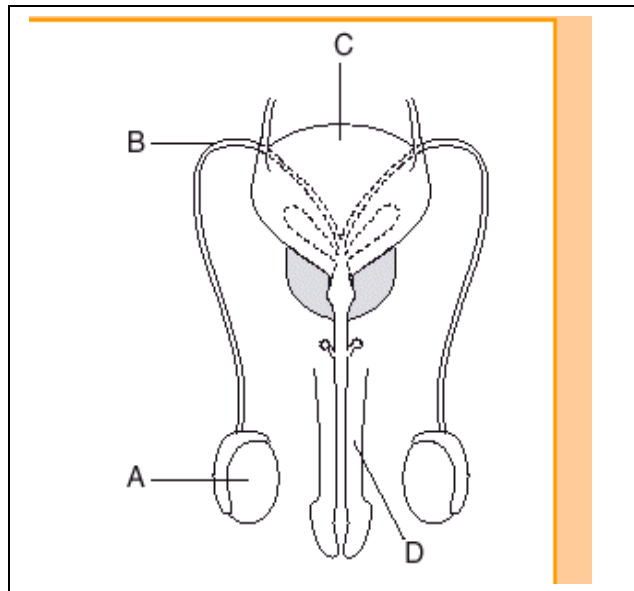
Sexual Reproduction

Male and Female Anatomy

GONADS
GAMETES
HORMONES

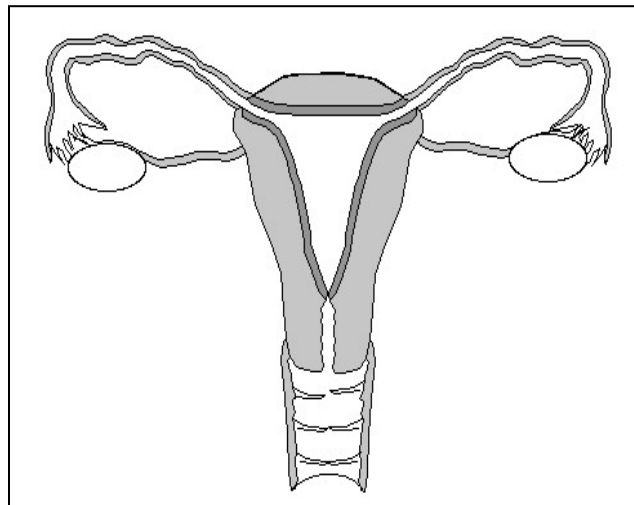
Male-

- A- testes
- B- Vas Defernce
- C Bladder
- D-Penis
- E-Urethra
- F-Epidydimus



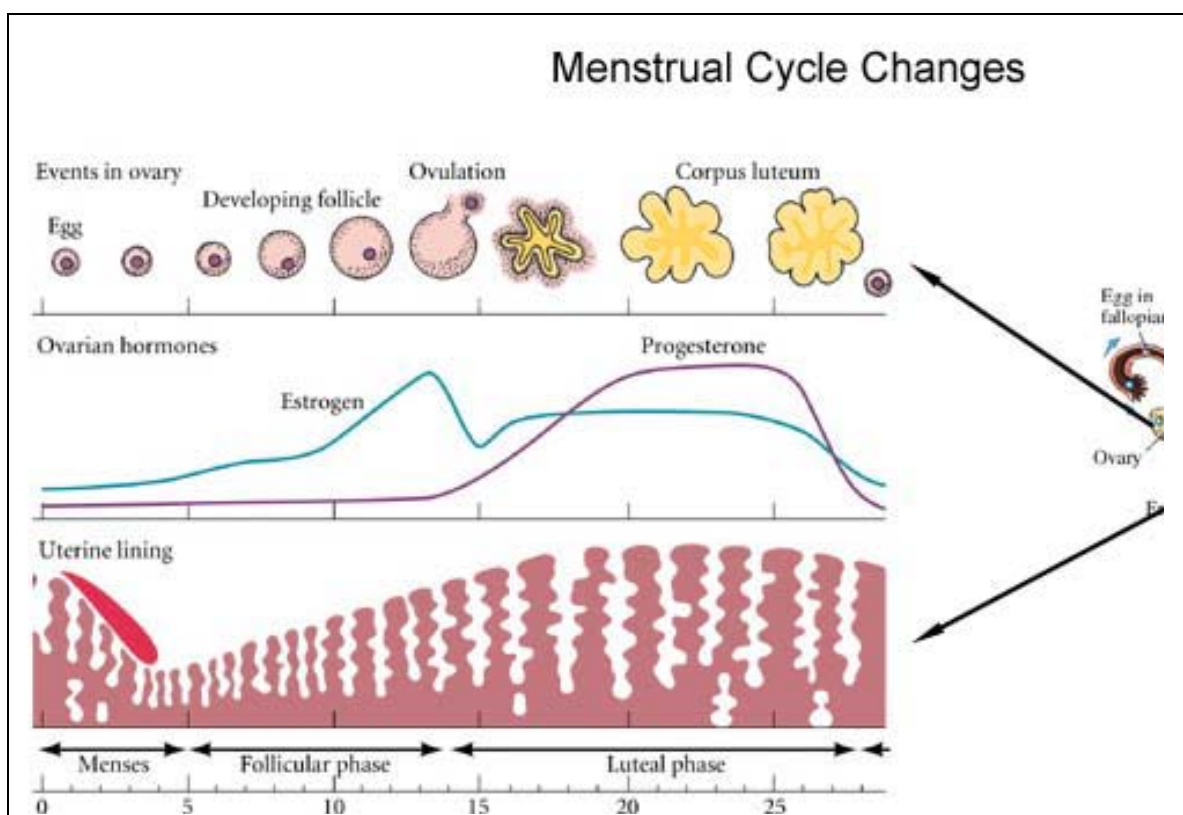
Female

- A-vagina
- B-cervix
- C-uterus
- D-oviduct/fallopian tube
- E ovary

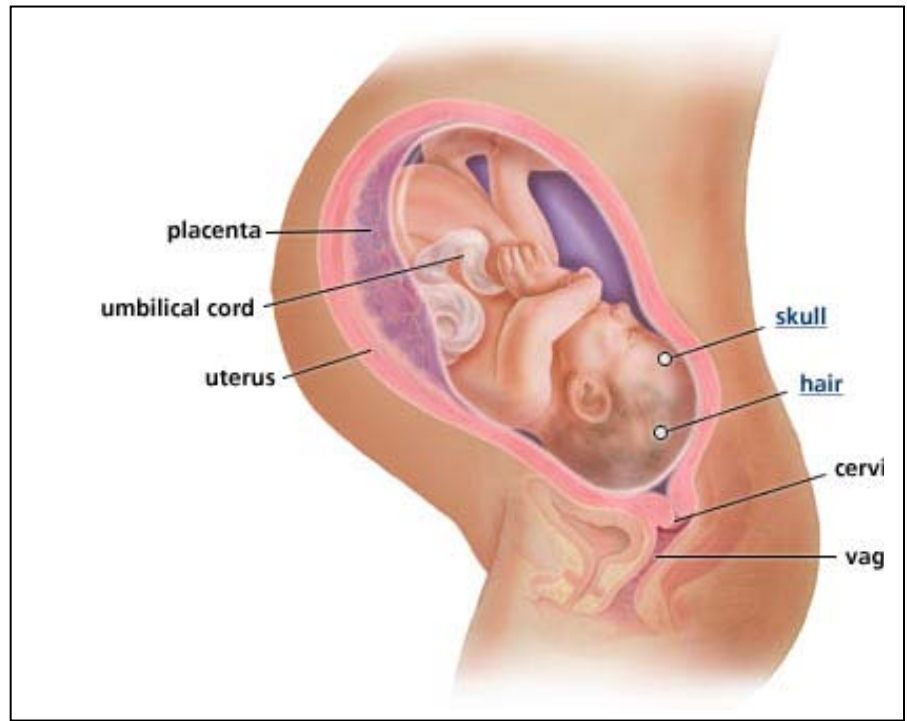


Menstrual cycle

- Estrogen builds the lining
- Progesterone maintains
- No fertilization- shedding of the lining=menstruation
- Temporary pause- pregnancy
- Permanent- menopause
- Day 14- Ovulation- egg is released



Uterus
 Placenta
 Umbilical cord
 Amnionic sac
 Gestation
 Prenatal
 postnatal
 Internal Fertilization- inside the oviducts
 Gestation- inside the uterus



External Development
 Birds, reptiles
 Yolk sac
 Amnion
 allantois

